

Mobile access

Artigo

Submetida 17 fev 2023

Aceita 26 fev 2023

Publicada 08 abr 2023

Autor Correspondente

Nome: R.H.S. Pinheiro

E-mail:

procamallanus@gmail.com

ISSN

2357-8068

URL

actapesca.news.com

DOI

[10.46732/actafish](https://doi.org/10.46732/actafish)

Indexadores/

Diretórios

Sumários

www.sumarios.org

Miguilim

<https://miguilim.ibict.br/>

Diadorim

Diadorim.ibict.br






Latindex

www.latindex.org

OPEN ACCESS

FIRST RECORD OF LARVAE OF *Hysterothylacium* (NEMATODA: RAPHIDASCARIDIDAE) INFECTING *Hoplias malabaricus* (CHARACIFORMES: ERYTHRINIDAE) IN PIAUÍ STATE, BRAZIL

Primeiro registro de larvas de *Hysterothylacium* (Nematoda: Raphidascarididae) infectando *Hoplias malabaricus* (Characiformes: Erythrinidae) no Estado do Piauí, Brasil

Raul Henrique da Silva Pinheiro¹ , Patrícia dos Reis Ferreira² , Fernanda Samara
Barbosa Rocha² , Simone Mousinho Freire²  & Elane Guerreiro Giese¹ 

¹Instituto da Saúde e Produção Animal, Universidade Federal Rural da Amazônia - UFR

²Laboratório de Zoologia e Biologia Parasitária, Universidade Estadual do Piauí - UESPI

RESUMO

Larvas de nematoide podem causar prejuízos ao pescado e doenças aos consumidores, assim registramos a primeira ocorrência de larvas de *Hysterothylacium* sp. in *Hoplias malabaricus* capturadas no Rio Poti, Estado do Piauí Nordeste do Brasil. Os peixes foram adquiridos mortos de pescadores artesanais ao chegarem das pescarias no rio Poti. Em laboratório os peixes foram investigados para a colheita de helmintos. Dezesesseis hospedeiros (63,3%) estavam parasitados por 94 larvas de nematoides e morfologicamente identificados como larvas de *Hysterothylacium* sp. parasitando o fígado, intestino, estômago, ceco pilórico, cavidade abdominal e bexiga natatória. A diversidade parasitaria em *H. malabaricus* é composta por trinta e dois táxons, sendo as larvas de *Contracaecum* dominante. Este trabalho registra o inventário parasitológico de nematoides em *H. malabaricus* e adicionamos dados morfológicos e morfométricos para larvas de *Hysterothylacium* sp. no Estado do Piauí, parasitando peixe de importância comercial.

Palavras-chave: Nematode, Parasito, Peixe, Água Doce, Nordeste, Brasil.

ABSTRACT

Nematode larvae can cause damage to fish and diseases to consumers. In this paper we record the first occurrence of *Hysterothylacium* sp. in *Hoplias malabaricus* captured by artisanal fishers in the Poti River, State of Piauí, northeast Brazil. In the laboratory the fish were investigated for the collection of helminths. Sixteen hosts (63.3%) were parasitized by 94 nematodes larvae that were morphologically identified as *Hysterothylacium* sp. parasitizing the liver, intestine, stomach, pyloric cecum, abdominal cavity and swim bladder. The parasitic diversity in *H. malabaricus* is composed of thirty-two taxa, with the larvae of *Contracaecum* being dominant. This work records the parasitological inventory of nematodes in *H. malabaricus* and we add morphological and morphometric data for *Hysterothylacium* sp. in the state of Piauí, parasitizing fish of commercial importance.

Keywords: Nematodes; Parasite, Freshwater fish, Northeast of Brazil.

INTRODUCTION

Helminths have been used as contemporary evidence of biodiversity and as organisms that enable monitoring of the state of the art of ecosystems; their presence or absence makes it possible to infer the richness of vertebrates and invertebrates in a given habitat (Brooks & McLennan, 1991). Many studies emphasize the evolutionary and ecological impact of parasitism (Bush et al., 1995). Thus, the host is the target of action of the parasite, and although they represent negative effects, the parasites can also constitute agents for control and conservation of biological biodiversity (Gardner & Campbell, 1992).

Among the countries of the American continent, South America is undoubtedly a region where parasite biodiversity is clearly underestimated (Morais et al., 2019). The large ichthyofauna of the region provides an enormous challenge to acquiring a basic knowledge of the fish helminth fauna of this continent (Luque & Poulin, 2007). Among vertebrates, fish have the highest rates of infection by parasites due to the unique characteristics of the aquatic environment, which facilitate the dissemination, reproduction and completion of the life cycle for each group of parasites. (Pereira et al., 2018).

Hoplias malabaricus (Bloch, 1794) has a wide geographical distribution and occurs in almost all hydrographic basins in South America (Santos et al., 2009). *Hoplias malabaricus* is one of the most inventoried species in parasitological studies, as it presents a vast and diverse helminth fauna, composed of adult parasites and larval forms (Paraguassú & Luque, 2007; Takemoto et al., 2009; Benigno et al., 2012; Reis et al., 2018; Pinheiro et al., 2020; Gião et al., 2020).

Within the Phylum Nematoda and superfamily Ascaridoidea the genus *Hysterothylacium* Ward & Magath, 1917, is composed of approximately 70 species and is considered one of the largest genera (Deardorff & Overstreet, 1981; Li et al., 2007; Rossin et al., 2011). *Hysterothylacium* larvae are parasites of fish in different aquatic environments worldwide (Guo et al., 2014). In Brazil, only three species have been mentioned, *H. fortalezae* (Klein, 1973) Deardorff & Overstreet, 1981, *H. eurycheilum* (Olsen, 1952) Deardorff & Overstreet, 1981 (Luque et al., 2011) and *H. deardorffoverstreetorum* Knoff, Felizardo, Iñiguez, Maldonado, Torres, Magalhães Pinto & Gomes, 2012 (Knoff et al., 2012). Different species of marine or freshwater fish can act as intermediate/ parathenic and/ or definitive hosts for the genus (Køie et al., 1993; Klimpel et al., 2005).

The host used in this study is one of the main freshwater fish species in the Parnaíba river basin, one of whose main tributaries is the Poti river (Ramos, 2012). This study was the first record of *Hysterothylacium* sp. parasitic larvae in *Hoplias malabaricus* (Bloch, 1794) captured in the Poti River in a freshwater environment in Piauí State, Brazil.

MATERIALS AND METHODS

Collection and examination of samples

Thirty specimens of *Hoplias malabaricus* were caught by fishermen in the Poti river, municipality of Teresina, Piauí state, Brazil. The dead fish were refrigerated and transported to the laboratory where they were weighed and measured (total length in cm). After the biometric analysis, the animals were necropsied, and the organs were removed, placed in Petri dishes with saline solution 0.9%, and examined using a stereomicroscope (LEICA ES2) and the nematodes were collected. The recovered nematodes were fixed in a solution of AFA (93 parts 70% ethyl alcohol, 5 parts formaldehyde, and 2 parts glacial acetic acid) and processed using light microscopy and scanning electron microscopy according to method described by Pinheiro et al. (2019). Measurements are shown in micrometers (μm) as the mean followed by the range, or as otherwise indicated.

The identification, classification and morphological terminology of *Hysterothylacium* larvae were made according to Cannon (1977), Moravec (1998), Bicudo et al. (2005), Anderson et al. (2009). The ecological indexes of parasitism were used according to Bush et al. (1997) and Bautista-Hernández et al. (2015).

Review of parasite in fish and deposit of specimens

A review of the records of parasites in *Hoplias malabaricus* in the national territory was made, evaluating the information present in databases with results available in articles and academic works (monograph, dissertations and theses).

Deposit of specimens

Five specimens (MPEG.NEM 000274), were deposited in the Coleção de Invertebrados não Arthropoda of the Museu Paraense Emílio Goeldi (MPEG), municipality of Belém, State of Pará, Brazil.

RESULT

PARASITOLOGICAL DATA

The specimens of *Hoplias malabaricus* had a length of 26.96 ± 11.69 cm (21–36 cm) and 241 ± 111.17 g (114.70–555.50 g) and were parasitized by nematodes larvae. All nematodes were measured and morphologically characterized, and the data confirmed the identification of these parasites as third-stage larvae of *Hysterothylacium* sp. (Nematoda: Raphidascarididae). Altogether, 94 larvae of *Hysterothylacium* sp. were found with a prevalence of 63.3% (19 infected, 30 examined); mean intensity = 5.9; mean abundance = 3; Range=1–64 for the analyzed fish, with the larvae being found in different organs (Table 1).

Table 1. Site of infection prevalence (P), mean intensity (MI), mean abundance (MA) and total number of parasites (TNP) in *Hoplias malabaricus* captured in the Poti river, state of Piauí, Brazil.

<i>Hysterothylacium</i> sp.	Hosts: <i>Hoplias malabaricus</i> (n = 30)			
Site of infection	P (%)	MI	MA	TNP
Liver ^a	6.7	1.5	0.1	3
Intestine	40.0	5.33	2.13	64
Stomach ^a	10.0	5.33	0.53	16
Pyloric caeca	20.0	1.5	0.3	9
Abdominal cavity ^a	3.3	1.0	0.03	1
Swimming bladder ^a	3.3	1.0	0.03	1

^aParasite found in the peritoneum of these organs.

MORPHOLOGICAL AND MORPHOMETRIC DATA

Hysterothylacium Ward & Magath, 1917

Hysterothylacium sp. (third-stage larvae) (Figure 1)

Description based on eight larvae: Medium size nematode when compared to other third stage larvae of the genus. Smooth transverse cuticles, lateral wing present. Body length 8mm (6–9mm); maximum width at ventriculus 200 (160–253). Head end rounded, provided with cuticular mounds surrounding mouth opening. Larval tooth absent. Nerve ring and excretory pore 244 (167–280) and 314 (267–340) from anterior end, respectively. Muscular slender esophagus, measuring 1mm (0.7–1mm) × 37 (27–47) (Figure 1A). The length ratio of the esophagus to body length is 10% (8–14 %). Size of ventriculus 59 (53–73) × 62 (47–67) (Figure 1B). Ventricular appendix 3 mm (3–4mm) long; ratio of ventricular appendix/ body length is 39% (34–44%). Intestinal caecum, extending anteriorly to the nerve ring, measuring 502 (333–667) × 58 (47–67). Rectum hyaline tube 95 (70–117). Three small and unicellular rectal glands are present. Tail conical 139 (117–173) long, with rounded tip without mucron (Figure 1C).

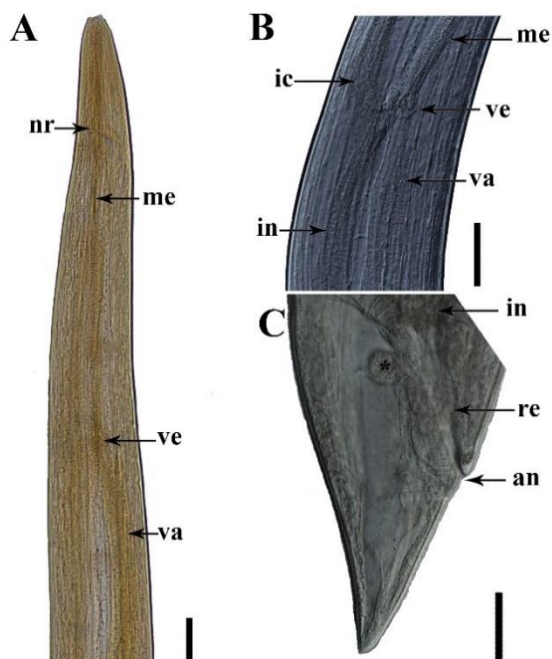


Figure 1. Light microscopy of *Hysterothylacium* sp. (larvae) parasite of *Hoplias malabaricus* captured in the Poti river, state of Piauí, Brazil: (a) Lateral view of the cephalic region showing evidence of the nerve ring (nr), muscular esophagus (me), ventricle (ve) and ventricular appendix (va). Bar = 100µm; (b) Detail end portion of muscular esophagus (me), intestinal caecum (ic), ventricle (ve) and ventricular appendix (va) Bar = 50µm; (c) Posterior portion, end portion of intestine (in), rectum (re), three unicellular rectal (*) glands and (a) anus, the tail without mucron. Bar = 50µm.

Morphological and morphometric data of third-stage larvae of *Hysterothylacium* sp. are shown below and in Table 2.

Table 2. Morphological and morphometric comparison of third-stage *Hysterothylacium* sp. collected from *Hoplias malabaricus* captured in the Poti river, state of Piauí and compared with *Hysterothylacium* larvae recorded by different authors parasitizing freshwater fish in Brazil.

Character	<i>Hysterothylacium</i> spp.				
	<i>Hoplias malabaricus</i>	<i>Rhaphiodon vulpinus</i> ^d	<i>Plagioscion squamosissimus</i>	<i>Arapaima gigas</i> ^h	<i>Astyanax fasciatus</i>
Hosts larvae	<i>Hoplias malabaricus</i>	<i>Rhaphiodon vulpinus</i> ^d	<i>Plagioscion squamosissimus</i>	<i>Arapaima gigas</i> ^h	<i>Astyanax fasciatus</i>
Grupo	Characiformes	Characiformes	Perciformes	Osteoglossiformes	Characiformes
Locality	Piauí	Paraná	Minas Gerais	Amazonas	Minas Gerais
Habitat	Freshwater	Freshwater	Freshwater	Freshwater	Freshwater
Prevalence	63.33%	–	44.1%	98%	59.46%
Length ^{a, b}	6–9	–	2.17–2.78 ^e	2.14–2.87	1.568–1.833
Width	160–253	–	80.6–104.8 ^e	90–125	12–78
Larval tooth	Absent	Present	Present	Present	–
Nerve ring ^c	167–280	129–147	95.7–146.8 ^e	100–137	105–125
Escretory pore ^c	267–340	144–171	85.1–148.9 ^e	110–132	100–125
Esophagus ^{a, L}	0.7–1	0.246–0.270	168.1–276.6	0.210–0.267	0.143–0.183
Esophagus ^W	27–47	–	19.1–23.4 ^e	–	–
Intestinal cecum ^L	333–667	24–33	21.3–42.5 ^e	50–160	25–28
Intestinal cecum ^W	47–67	–	–	–	–
Ventriculus ^L	53–73	15–18	–	25–50	15–64
Ventriculus ^W	47–67	18	19.1–40.4 ^{e, f}	–	20–28
Ventricular appendix ^{a, L}	3–4	0.857–0.966	0.564–1.032	0.625–0.975	0.713–0.880
Tail	117–173	51–63	63.8–82.9 ^{e, g}	62–100	48–55
Mucron	Absent	Absente	Present	Absent	–
Nº of specimens	15	5	21	10	10
Reference	Present study	Moravec et al. (1993)	Martins et al. (2000)	Andrade-Porto et al. (2015)	Vieira-Menezes et al. (2017)

^aMeasurements in millimeters indicated;

^bAbbreviations: L: length, W: width.

^cDistance from anterior end to;

^dOther hosts cited by Moravec, Kohn, Fernandes 1993: *Salminus brasiliensis* (Cuvier, 1816) (Characiformes: Bryconidae) (Syn. *Salminus maxillosus*), *Galeocharax knerii* (Steindachner, 1879) (Characiformes: Characidae), *Hypophthalmus edentates* Spix & Agassiz, 1829 (Siluriformes: Pimelodidae), *Pterodoras granulosus* (Valenciennes, 1821) (Siluriformes: Doradidae), *Plagioscion squamosissimus* (Heckel, 1840) (Perciformes, Sciaenidae), *Crenicichla lepidota* Heckel, 1840 (Cichliformes: Cichlidae) and *Loricariichthys* sp. (Siluriformes: Loricariidae);

^eMeasurements obtained in mm second Martins et al. (2000);

^fMartins et al. (2000) uses esophageal bulb terminology for the ventriculus;

^gAlthough the authors do not write the non-occurrence of mucron, the same can be observed in the scientific illustrations present in the article;

^hFish produced in an aquaculture system.

The *Hoplias malabaricus* nematofauna demonstrated a biodiversity composed of 32 species of nematodes between larvae and adults, with unidentified individuals also being recorded, with the intestine, abdominal cavity and stomach being the main infection sites. Regarding biogeography there are records of parasites in this fish from 15 states (AP, CE, ES, MA, MG, MS, MT, PA, PR, RJ, RO, RS, SC, SP, TO). The superfamily Ascaridoidea showed greater wealth, with four families (Anisakidae, Ascarididae, Heterocheilidae and Raphidascaididae) and eight registered species. *Contraecum* larvae showed dominance in the records as parasites of *Hoplias malabaricus*, being cited in nine different states in Brazil (Table 3).

Table 3. Nematodes parasites of *Hoplias malabaricus* distribution in Brazilian territory according to register made for differences researchers between 1915 and 2020.

Superfamily/ Family/ Parasite	Site of infection ^a	Location ^b	References ^c
Superfamily Ascaridoidea Railliet & Henry, 1915			
Family Raphidascarididae Hartwich, 1974			
<i>Hysterothylacium</i> sp. (Larvae)	IN, SB, AC, PC, LI	PI, SP, MG	Pereira (2010) ^{d, e} , Corrêa et al. (2020) ^e
Family Anisakidae Skrjabin & Karokhin, 1945			
<i>Contracaecum multipapillatum</i> (von Drasche, 1882)	DT, MU, AC	MT	Barros et al. (2004) ^f , Fontenelle et al. (2017) ^e Fábio (1982), Vicente et al. (1985) ^d , Kohn et al. (1988), Weiblen; Brandão, (1992), Moravec et al. (1993), Moravec (1998) ^d , Vicente; Pinto (1999) ^d , Martins et al. (2003), Madi; Silva, (2005), Martins et al. (2005), Paraguassú (2006) ^d , Paraguassú; Luque, (2007), Barros et al. (2007), Justino; Barros (2008), Takemoto et al. (2009), Rodrigues (2010) ^d , Eiras et al. (2010) ^d , Rocha (2011), Luque et al. (2011) ^d , Benigno (2011) ^d , Benigno et al. (2012), Alcântara; Tavares-Dias (2015), Gonçalves et al. (2016), Eiras et al. (2016) ^d , Rodrigues et al. (2017), Carvalho et al. (2017), Oliveira et al. (2018), Oliveira et al. (2019), Corrêa et al. (2020), Gião et al. (2020)
<i>Contracaecum</i> sp. (Larvae)	PE, IN, LI, ST, ME, MU, AC, OV	RJ, PR, SP, MT, PA, AP, MA, RS, MG	Gião et al. (2020) Vicente et al. (1985) ^d , Moravec (1998) ^d , Takemoto et al. (2009), Eiras et al. (2010) ^d , Luque et al. (2011) ^d , Corrêa et al. (2020) Rodrigues et al. (2017)
<i>Goezia brasiliensis</i> Moravec, Kohn & Fernandes, 1994	-	SP	Gião et al. (2020) Vicente et al. (1985) ^d , Moravec (1998) ^d , Takemoto et al. (2009), Eiras et al. (2010) ^d , Luque et al. (2011) ^d , Corrêa et al. (2020) Rodrigues et al. (2017)
<i>Goezia spinulosa</i> (Diesing, 1839)	IN, ST	SP, PR	
<i>Pseudoterranova</i> sp. (Larvae)	ME	MA	
Family Ascarididae Baird, 1853			
<i>Amplichaecum</i> sp. (Larvae)	IN	SP	Kohn; Fernandes, (1987), Moravec (1998) ^d , Vicente; Pinto (1999) ^d , Luque et al. (2011) ^d
<i>Porrocaecum</i> sp. (Larvae)	AC	PR	Takemoto et al. (2009), Eiras et al. (2010) ^d ,

			Luque et al. (2011) ^d
Family Heterocheilidae Railliet & Henry, 1915			
<i>Brevimulticaecum</i> sp. (Larvae)	AC, LI, BC, ME, MU, ST	MS	Vieira et al. (2010), Luque et al. (2011) ^d , Tavares et al. (2017) ^d
Superfamily Camallanoidea Travassos, 1920			
Family Camallanidae Railliet & Henry, 1915			
<i>Spirocamallanus inopinatus</i> Travassos, Artigas & Pereira, 1928	IN, PC, ST, AC	SP, RJ, PR, AP	Pinto et al. (1974) ^g , Pinto; Noronha (1976), Fábio (1982), Vicente et al. (1985) ^d , Kohn; Fernandes, (1987), Moravec (1998) ^d , Thatcher (2006) ^{d, g} , Takemoto et al. (2009), Eiras et al. (2010) ^d , Luque et al. (2011) ^d , Alcântara; Tavares-Dias, (2015), Eiras et al (2016) ^d , Gonçalves et al. (2016) ^e , Corrêa et al. (2020), Gião et al. (2020) Vicente et al. (1985) ^d , Kohn; Fernandes (1987), Moravec (1998) ^d , Eiras et al. (2010) ^d , Luque et al. (2011) ^d , Corrêa et al. (2020)
<i>Spirocamallanus ihering</i> Travassos, Artigas & Pereira, 1928	IN	SP	Rodrigues et al. (1991), Weiblen; Brandão, (1992), Moravec (1998) ^d , Eiras et al. (2010) ^d , Luque et al. (2011) ^d , Corrêa et al. (2020)
<i>Spirocamallanus hilarii</i> (Vaz & Pereira, 1934)	IN	RS, SP, MG	Eiras et al. (2010) ^d , Luque et al. (2011) ^d , Carvalho et al. (2017), Corrêa et al. (2020)
<i>Spirocamallanus amarali</i> Vaz & Pereira, 1934	IN	SP	Corrêa et al. (2020)
<i>Spirocamallanus</i> sp.	IN	SP	Vicente et al. (1985) ^d , Luque et al. (2011) ^d
<i>Procamallanus peraccuratus</i> Pinto, Fábio Noronha & Rolas, 1976	IN	RS, PR	Weiblen; Brandão, (1992), Takemoto et al. (2009), Eiras et al. (2010) ^d , Luque et al. (2011) ^d
<i>Procamallanus</i> sp.	ME, IN	PA, ES	Vicente et al. (1985) ^d , Luque et al. (2011) ^d , Benigno (2011) ^d , Benigno et al. (2012)
Superfamily Cosmocercoidea Railliet, 1916			
Family Atracttidae Railliet, 1917			
<i>Klossinemella iheringi</i> (Travassos, Artigas & Pereira, 1928)	IN, PC	PR, SP	Vicente et al. (1985) ^d , Moravec (1998) ^d , Thatcher (2006) ^d , Eiras et al. (2010) ^d , Luque et al. (2011) ^d
Superfamily Diactophymatoidea Railliet 1915 (Roman 1965)			
Family Diactophymatidae (Railliet, 1915)			

<i>Eustrongylides ignotus</i> Jäegerskiöld, 1909	MU, AC	PR, MG, MT	Moravec (1998) ^d , Vicente; Pinto, (1999) ^d , Barros et al. (2004), Takemoto et al. (2009) ^e , Eiras et al. (2010) ^d , Luque et al. (2011) ^d , Eiras et al. (2016) ^d , Carvalho et al. (2017) ^e
<i>Eustrongylides</i> sp. (Larvae)	MU, ME, LI, ST, IN, AC	SP, MT, RS PA, RO, TO MA, RJ, SC	Moravec (1998) ^d , Barros et al. (2007), Martins et al. (2009), Rodrigues (2010) ^d , Eiras et al. (2010) ^d , Luque et al. (2011) ^d , Rocha (2011), Benigno (2011) ^d Benigno et al. (2012), Meneguetti et al. (2013), Reis (2014) ^d , Eiras et al. (2016) ^d , Rodrigues et al. (2017), Oliveira et al. (2019), Kuraiem et al. (2020), Corrêa et al. (2020), Gião et al. (2020), Gueretz et al. (2020)
Superfamily Dracunculoidea Stiles, 1907			
Family Guyanemidae Petter, 1975			
<i>Guyanema baudi</i> Petter & Dlouhy 1985	AC	RS, SP	Weiblen; Brandão (1992), Moravec (1998) ^d , Thatcher (2006) ^d , Gião et al. (2020)
<i>Guyanema raphiodoni</i> Moravec, Kohn & Fernandes, 1993	–	PR	Kohn et al. (2011) ^d
Family Philometridae Baylis & Daubney, 1926			
<i>Philonema</i> sp.	AC	SP	Vicente et al. (1985) ^d , Luque et al. (2011) ^d
Superfamily Gnathostomatoidea Railliet, 1895			
Family Gnathostomatidae Railliet, 1895			
<i>Spiroxys contortus</i> (Rudolphi, 1819)	–	SP	Gião et al. (2020)
Superfamily Habronematoidea Ivaschkin, 1961			
Family Cystidicolidae Skrjabin, 1946			
<i>Cystidicoloides izecksohni</i> (Fábio, 1982)	ST, GI	RJ	Fábio (1982), Vicente et al. (1985) ^d , Moravec (1998) ^d , Thatcher (2006) ^{d, h} , Eiras et al. (2010) ^d , Luque et al. (2011) ^d
<i>Cystidicoloides</i> sp. (Larvae)	ST	AP	Gonçalves et al. (2016)
<i>Pseudoproleptus</i> sp. (Larvae)	ME, IN	AP	Oliveira et al. (2018)
<i>Spinitectus rodolphihering</i> Vaz & Pereira, 1934	–	SP	Gião et al. (2020)
Superfamily Seuratoidea Hall, 1916			
Family Quimperiididae Gendre, 1928			
<i>Paraseuratum soaresi</i> Fábio, 1982	IN	RJ, SP, RS	Fábio (1982), Vicente et al. (1985) ^d ,

<i>Paraseuratum</i> sp.	AC	SP	Weiblen; Brandão, (1992), Moravec (1998) ^d , Thatcher (2006) ^d , Eiras et al. (2010) ^d , Luque et al. (2011) ^d , Corrêa et al. (2020) Vicente et al. (1985) ^d , Luque et al. (2011) ^d
Superfamily Thelazioidea Skrjabin, 1915			
Family Rhabdochonidae Skrjabin, 1946			
<i>Rhabdochona acuminata</i> (Molin, 1860)	IN	SP	Corrêa et al. (2020)
Superfamily Trichinelloidea Ward, 1907			
Family Capillariidae Railliet, 1915			
<i>Capillostrongyloides sentinosa</i> (Travassos, 1927)	ST	SP	Vicente et al. (1985) ^d , Moravec (1998) ^d , Thatcher (2006) ^{d,i} , Eiras et al. (2010) ^d , Luque et al. (2011) ^d Vicente et al. (1985) ^d , Weiblen; Brandão, (1992), Moravec (1998) ^d , Takemoto et al. (2009), Eiras et al. (2010) ^d , Luque et al. (2011) ^{d,j}
<i>Paracapillaria</i> (<i>Paracapillaria</i>) <i>piscicola</i> Travassos, Artigas & Pereria, 1928) Mendonça, 1963	IN, ST	RS, PR, SP	Vicente et al. (1985) ^d , Moravec (1998) ^d , Thatcher (2006) ^{d,i} , Eiras et al. (2010) ^d , Luque et al. (2011) ^d Vicente et al. (1985) ^d , Weiblen; Brandão, (1992), Moravec (1998) ^d , Takemoto et al. (2009), Eiras et al. (2010) ^d , Luque et al. (2011) ^{d,j}
Phylum Nematoda (Rudolphi, 1808)			
Indeterminate (adult and larva)	ST, IN	SP, RS, CE	Khon et al. (1985) ^e , Weiblen; Brandão, (1992) ^e , Kohn et al. (2004), Luque et al. (2011) ^d

^aAbbreviations of Site in host: Abdominal cavity - AC; Digestive tract - DT; Gills - GI; Intestine - IN; Liver - LI; Mesenteries - ME; Muscle - MU; Ovary - OV; Peritônio - PE; Pyloric caeca - PC; Stomach - ST; Swim bladder - SB;

^bAbbreviations of States: Amapá - AP; Ceará - CE; Espírito Santo - ES; Maranhão - MA; Mato Grosso - MT; Mato Grosso do Sul - MS; Minas Gerais - MG; Pará - PA; Paraná - PR; Piauí - PI; Rio de Janeiro - RJ; Rio Grande do Sul - RS; Rondônia - RO, Santa Catarina -SC; São Paulo - SP;

^crecords bibliographical by host in chronological sequence;

^dData obtained by parasite review books, monographs, dissertations and theses;

^ePara forma imaturas (L3)

^fPara forma imaturas (L4)

^gPara *Spirocamallanus wrighti* (Pereira 1935), Sinonimo of *S. inopinatus*.

^hPara *Heliconema izecksohni* (Fábio, 1982).

ⁱPara *Capillaria zederi* (Texeira de Freitas & Lent, 1935), Sinonimo of *Capillostrongyloides sentinosa*;

^jSyn. *Capillaria piscicola* (Travassos, Artigas & Pereira, 1928).

DISCUSSION

The nematodes recovered from the intestine of *H. malabaricus* captured in the Poti River, present morphology compatible with the third stage larvae of *Hysterothylacium*. Different authors have demonstrated the characterization of larvae of the Raphidascarididae family as parasites of Brazilian ichthyofauna and presented important information for the diagnosis of third-stage larvae of *Hysterothylacium* (Moravec, 1998; Felizardo et al., 2009; Fonseca et al., 2016; Pantoja et al., 2016; Di Azevedo & Iñiguez, 2018).

In this study, we have expanded the biogeographic distribution of the genus *Hysterothylacium* to the state of Piauí, northeastern Brazil. In the national territory Pereira (2010) recorded the occurrence and prevalence of *Hysterothylacium* larvae parasitizing the liver (0.08%), intestine (8.93%), pyloric caeca (8.93%) and, abdominal cavity (1.54%) of *H. malabaricus* captured in the Furnas reservoir (Minas Gerais)

and warned of the possible zoonotic potential of the harvested parasites. Corrêa et al. (2020) registered the presence of 6.42% of larvae of this genus in the swim bladder of *Hoplias aff. malabaricus* caught in the Mogi-Guaçu River, state of São Paulo. The same infection sites presented by the authors are described in this work with larvae recovered from the liver, intestine, stomach, pyloric caeca, abdominal cavity and swim bladder. The prevalence distributed by site of infection is shown in Table 1.

Morphometrically the *Hysterothylacium* larvae in our study were 6–9mm long. Listing the larvae recovered from freshwater fish recorded in different studies in Brazil one finds: 2.17–2.78mm in *Plagioscion Squamosissimus* (Heckel, 1840) (Perciformes, Sciaenidae) (MARTINS et al., 2000), 2.14–2.87mm in *Arapaima gigas* (Schinz, 1822) (Osteoglossiformes: Osteoglossidae) (ANDRADE-PORTO et al., 2015), 1.568–1.833mm in *Psalidodon fasciatus* (Cuvier, 1819) (Syn. *Astyanax fasciatus*) (Characiformes: Characidae) (Vieira-Menezes et al., 2017). We can observe a larger body size, and the larvae in this study also had a ventricular appendix (3–4mm) that was larger than what was recorded for freshwater fish larvae in general. When comparing the *Hysterothylacium* larvae found in marine fish, the variation in body width of the larvae present in these fish was notable: 1.65–4.05mm in *Micropogonias furnieri* (Desmarest, 1823) (Perciformes, Sciaenidae) (Pereira Jr. et al., 2004), 2.97–23.13mm in *Prionotus punctatus* (Bloch, 1793) (Perciformes: Triglidae) (Bicudo et al., 2005), 3.62–16.7mm in *Paralichthys isosceles* Jordan, 1891 (Pleuronectiformes: Paralichthyidae) (Felizardo et al., 2009), 11.16–19.02mm in *Trachinotus carolinus* (Linnaeus, 1766) (Carangiformes: Carangidae), 12.60–13.70mm in *Chaetodipterus faber* (Broussonet, 1782) (Acanthuriformes: Ephippidae) (Ribeiro et al., 2014), 12.3–17.7mm in *Micropogonias furnieri* (Desmarest, 1823) (Perciformes: Sciaenidae), 14–15mm in *Genypterus brasiliensis* Regan, 1903 (Ophidiiformes: Ophidiidae), 10–18mm in *Mullus argentinae* Hubbs & Marini, 1933 (Mulliformes: Mullidae) (Di Azevedo & Iñiguez, 2018). In order to better illustrate the morphological variation present among *Hysterothylacium* larvae, Table 2 presents morphological and morphometric data for the *Hysterothylacium* parasites of *H. malabaricus* in this study, compared with data from larvae recovered from different freshwater hosts in Brazil.

This wide variation in the size of the larvae may be related to the life cycle of nematodes of the genus *Hysterothylacium*. In the life cycle of *Hysterothylacium*, fish are definitive hosts, while crustaceans can host the larvae and act as intermediate hosts (Anderson, 2009). For Pavanelli et al. (2015) when *Hysterothylacium* larvae are 3 mm long and are ingested, they undergo metamorphosis to L4 reaching maturity in the intestine of the definitive host fish; however, smaller larvae when ingested by other fish may not survive or may encyst in the organ serosa of the celomic cavity, not developing the cycle and waiting to reach their definitive host. In these cases, the host would act as a paratenic host. In this study, *H. malabaricus* can act as intermediate and paratenic hosts for *Hysterothylacium* larvae, since the highest prevalence of infection was in the intestine (40%), in addition to specimens encysted in the organ serosa.

Although the occurrence of hysterothylaciosis in humans in Brazil has not been described in the literature, Fontenelle et al. (2013) warn of the zoonotic potential of Anisakidae and Raphidascarididae nematode larvae present in fish marketed for consumption in Brazil. Eiras et al. (2015) reinforces that the scarcity of information for cases of infections in humans by *Hysterothylacium* larvae does not allow the establishment of a symptomatological picture. Among the infections registered for representatives of *Hysterothylacium*, Overstreet; Meyer (1981) when inoculating primates with larvae of *Hysterothylacium* sp. recorded the presence of hemorrhagic lesions in the stomach, which suggests that this species may present a potential zoonotic risk. Subsequently, cases of human infection with *Hysterothylacium aduncum* have been recorded (Yagi et al., 1996; González-Amores et al., 2015).

Among the most prevalent and abundant nematodes with a biogeographical distribution that coincides with that of *Hoplias malabaricus* are the those in the genus *Contracaecum* and their larvae (Anisakidae). Pinheiro et al. (2019) registered the presence of larvae of this genus in 140 species and a fish hybrid morphotype. Within this diversity of fish, the host of this study was one of the most cited as intermediate/paratenic host for larvae of this genus with distribution in eight states (RJ, PR, SP, MT, PA, AP, MA, RS). In addition to infection by *Contracaecum* larvae, other adult nematodes and larvae with zoonotic potential are recorded as parasitizing *H. malabaricus*. In Table 3 we present the inventory of the *H. malabaricus* nematofauna in the national territory.

Thirty-two adult parasites and larval forms were recorded, of which *Hysterothylacium* sp., *Pseudoterranova* sp. and *Contracaecum* sp. are cited as zoonotic. The parasitic nematodes of fish recorded in the scientific literature as causing disease in humans are *Anisakis* spp., *Pseudoterranova* spp., *Gnathostoma* spp., *Capillaria philippinensis*, and, more rarely, infections with *Hysterothylacium aduncum*, *Contracaecum* spp., *Eustrongylides* spp. and *Dioctophyme renale* (Goeze, 1782) (Nematoda:

Diectophymatidae), *Angiostrongylus cantonensis* (Chen, 1935) (Nematoda: Angiostrongylidae) (Cross, 1992; Thobois et al., 1996; Yagi et al., 1996; Barriga et al., 1999; Cabrera et al., 2003; Ignatovic et al., 2003; Shamsi & Butcher, 2011; Eberhard & Ruiz-Tiben, 2014; Cornaglia et al., 2016; Eiras et al., 2018).

Hoplias malabaricus is a carnivorous species, preferably piscivorous as an adult, but feeding on plankton, crustaceans, insects and seeds when young (Santos et al., 2006; Pinheiro et al., 2020). This vast capacity for exploiting the food available in the environment as it grows, makes this species important in the life cycle of different parasites present in the aquatic environment. Machado et al. (2013) state that the diet facilitates the life cycles of the parasites, since a broader diet facilitates the arrival of the parasite to the definitive host, thus saving energy; however improper encounters can happen (paratenic or accidental hosts such as human parasitism). The same authors state that top-of-the-chain fish have few predators, but a great diversity of parasites, which indicates a vulnerability within aquatic ecosystems.

CONCLUSION

Hoplias malabaricus possibly acts as an intermediate and paratenic host of *Hysterothylacium* larvae in the Poti River. Although the information on the zoonotic potential for this genus is imprecise, we highlight the importance of health studies in fish markets, especially when fish like *Hoplias malabaricus* are widely used as a food base by the population not only in the State of Piauí, but also in others such as Maranhão, Pará, São Paulo, Amazonas and Amapá.

ACKNOWLEDGMENTS

The author is grateful to the following the Laboratório de Zoologia e Biologia Parasitária and Laboratório de Histologia e Embriologia Animal for the use of laboratory. Dra. Elane Giese was supported by a researcher fellowship of Conselho Nacional de Pesquisa e Desenvolvimento Tecnológico (CNPq-Brasil) (#313763/2020-8).

REFERENCES

- Alcântara, N.M. & Tavares-Dias, M. (2015) Structure of the parasites communities in two Erythrinidae fish from Amazon River system (Brazil). *Rev. Bras. Parasitol. Vet.*, 24(2): 183-190. <http://dx.doi.org/10.1590/S1984-29612015039>
- Anderson, R.C., Chabaud, A.G. & Willmott, S. (2009). *Keys to the nematode parasites of vertebrates*. Wallingford: CABI International. <http://dx.doi.org/10.1079/9781845935726.0000>
- Andrade-Porto, S.M., Cárdenas, M.B., Martins, M.L., Oliveira, J.K.Q., Pereira, J.N., Araújo, C.S.O. & Malta, J.C.O. (2015). First record of larvae of *Hysterothylacium* (Nematoda: Anisakidae) with zoonotic potential in the pirarucu *Arapaima gigas* (Osteichthyes: Arapaimidae) from South America. *Braz. J. Biol.*, 75(4): 790-795. <http://dx.doi.org/10.1590/1519-6984.22213>
- Barriga, J., Salazar, F. & Barriga, E. (1999). Anisakiasis: presentación de um caso y revisión de la literatura. *Rev. Gastroenterol. Peru.*, 19(4): 317-323.
- Barros, L.A., Moraes, J.F.O. & Oliveira, R.L. (2007). Nematode larvae with zoonotical importance found in traíras (*Hoplias malabaricus*) in Santo Antonio do Leverger, Mato Grosso, Brazil. *Arq. Bras. Med. Vet. Zootec.*, 59(2): 533-535. <http://dx.doi.org/10.1590/S0102-09352007000200042>.
- Barros, L.A., Tortelly, R., Pinto, R.M. & Gomes, D.C. (2004). Effects of experimental infections with larvae of *Eustrongylides ignotus* Jäegerskiöld, 1909 and *Contracaecum multipapillatum* (Drasche, 1882) Baylis, 1920 in rabbits. *Arq. Bras. Med. Vet. Zootec.*, 56: 325-332. <http://dx.doi.org/10.1590/S0102-09352004000300007>
- Bautista-Hernández, C.E., Monks, S., Pulido-Flóres, G. & Rodríguez-Ibarra, A.E. (2015). Revisión bibliográfica de algunos términos ecológicos usados en parasitología, y su aplicación en estudios de caso. In: *Estudios em biodiversidad*. vol. I. Lincoln, Nebraska: Zea Books, p. 11-19.
- Benigno, R.N.M., CLEMENTE, S.C., MATOS, E.R., PINTO, R.M., GOMES, D.C. & Knoff, M. (2012) Nematodes in *Hoplerythrinus unitaeniatus*, *Hoplias malabaricus* and *Pygocentrus nattereri* (Pisces Characiformes) in Marajó Island, Brazil. *Rev. Bras. Parasitol. Vet.*, 21(2): 165-170. <https://doi.org/10.1590/S1984-29612012000200018>

Benigno, R.N.M. (2011). Helmintos de interesse higiênico-sanitário coletados em *Hoplerytinus unitaeniatus*, *Hoplias malabaricus* e *Pygocentrus nattereri* (Pisces Characiformes) procedentes do lago Arari (ilha de Marajó), Pará – Brasil. Tese de doutorado, Universidade Federal Fluminense, Niterói, Rio de Janeiro, Brasil.

Bicudo, A.J.A., Tavares, L.E.R. & Luque, J.L. (2005). Anisakidae larvae (Nematoda: Ascaridoidea) parasites of the bluewing searobin *Prionotus punctatus* (Bloch, 1793) (Osteichthyes: Triglidae) from the coastal zone of the State of Rio de Janeiro, Brazil. *Rev. Bras. Parasitol. Vet.*, 14(3): 109-118.

Brooks, D.R. & McLennan, D.A. (1991). Phylogeny, ecology, and behavior: A research program in comparative biology. Chicago, University of Chicago Press.

Bush, A.O., Lafferty, K.D., Lotz, J.M. & Shostak, A.W. (1997). Parasitology meets ecology on its own terms: Margolis et al. revisited. *J. Parasitol.*, 83(4): 575-583. <http://dx.doi.org/10.2307/3284227>. PMID:9267395.

Cabrera, R., Luna-Pineda, M. & Suárez-Ognio, L. (2003). Nuevo caso de infección humana por una larva de *Pseudoterranova decipiens* (Nematoda, Anisakidae) en el Perú. *Rev. Gastroenterol. Peru.*, 23(3): 217-220.

Cannon, L.R.G. Some ecological relationships of larval ascaridoids from south-eastern Queensland marine fishes. (1977). *Int. J. Parasitol.: Parasites Wildl.*, 7(3): 227-232. [https://doi.org/10.1016/0020-7519\(77\)90052-2](https://doi.org/10.1016/0020-7519(77)90052-2)

Carvalho, A.R., Martins, R.T., Bellei, P.M. & Lima, S.S. (2017). Aspectos ecológicos da helmintofauna de *Hoplias malabaricus* (Bloch, 1794) (Characiformes, Erythrinidae) da Represa Dr. João Penido (Juiz de Fora-MG, Brasil). *Rev. Bras. Zootecias.*, 18(1): 7-20. <https://doi.org/10.34019/2596-3325.2017.v18.24413>

Cornaglia, J., Jean, M., Bertrand, K., Aumaître, H., Roy, M. & Nickel, B. (2016). Gnathostomiasis in Brazil: an emerging disease with a challenging diagnosis. *J. Travel Med.*, 24(1): 1-4. <http://dx.doi.org/10.1093/jtm/taw074>.

Corrêa, L.L., Takemoto, R.M., Ueta, M.T. & Adriano, E.A. (2020). New records and prevalence of metazoan parasites of fish in the southeastern Brazilian region. *Ann. Parasitol.*, 66(1): 27-37. <http://dx.doi.org/10.17420/ap6601.235>

Cross, J.H. (1992). Intestinal capillariasis. *Clin. Microbiol. Rev.*, 5(2): 120-129.

Deardorff, T.L. & Overstreet, R.M. (1981). Larval *Hysterothylacium* (= *Thynnascaris*) (Nematoda: Anisakidae) from fishes and invertebrates in the Gulf of Mexico. *Proc. Helminthol. Soc. Wash.*, 48(2): 113-126.

Di Azevedo, M.I.N. & Iñiguez, A.M. (2018). Nematode parasites of commercially important fish from the southeast coast of Brazil: Morphological and genetic insight. *Int J Food Microbiol.*, 267: 29-41. <https://doi.org/10.1016/j.ijfoodmicro.2017.12.014>

Eberhard, M.L. & Ruiz-Tiben, E. (2014). Case report: cutaneous emergence of *Eustrongylides* in two persons from Sudan. *Am. J. Trop. Med. Hyg.*, 90(2): 315-317. <https://doi.org/10.4269/ajtmh.13-0638>

Eiras, J.C., Pavanelli, G.C., Takemoto, R.M. & Nawa, Y. (2018). Fish-borne nematodiasis in South America: neglected emerging diseases. *J. Helminthol.*, 92(6): 649-654. <https://doi.org/10.1017/S0022149X17001006>

Eiras, J.C., Pavanelli, G.C., Takemoto, R.M., Yamaguchi, M. U., Karkling, L. C. & Nawa Y. (2016). Potential risk of fish-borne nematode infections in humans in Brazil-Current status based on a literature review. *Food Waterborne Parasitol.*, 5: 1-6. <http://dx.doi.org/10.1016/j.fawpar.2016.08.002>.

Eiras, J.C., Pavanelli, G.C., Yamaguchi, U.M., Takemoto, R.M., Bernunci, M. P., Sellas, D.E., Alvarenga, F.M., Pacheco, G.G., Karling, L.C. & Calça, V.C. (2015). Zoonoses causadas pelos nematodas. In: Pavanelli, G.C.; Eiras, J.C.; Yamaguchi, U.M.; Takemoto, R.M. *Zoonoses humanas transmissíveis por peixes no Brasil*. Maringá, Paraná, p. 61-111.

Eiras, J.C., Takemoto, R.M. & Pavanelli, G.C. (2010). *Diversidade dos parasitas de peixes de água doce*

do Brasil. Cliche Tec Editora, Maringá, Paraná.

Fábio, S.P. (1982). Sobre alguns nematodas parasitos de *Hoplias malabaricus*. *Arq. Univer. Fed. Rur. Rio de Janeiro.*, 5(2): 179-186.

Felizardo, N.N., Menezes, R.C., Tortelly R., Knoff, M., Pinto, R.M. & Gomes, D.C. Larvae of *Hysterothylacium* sp. (Nematoda: Anisakidae) in the sole fish *Paralichthys isosceles* Jordan, 1890 (Pisces: Teleostei) from the littoral of the state of Rio de Janeiro, Brazil. *Vet. Parasitol.*, 166(1-2): 175-177, 2009. <https://doi.org/10.1016/j.vetpar.2009.08.004>

Fonseca, M.C.G., Knoff, M., Felizardo, N.N., Di Azevedo, M.I.N., Torres, E.J.L., Gomes, D.C., Iñiguez, A.M. & São Clemente, S.C. Integrative taxonomy of Anisakidae and Raphidascarididae (Nematoda) in *Paralichthys patagonicus* and *Xystreurys rasile* (Pisces: Teleostei) from Brazil. *Int. J. Food Microbiol.*, 235: 113-124, 2016. <https://doi.org/10.1016/j.ijfoodmicro.2016.07.026>

Fontenelle, G., Knoff, M., Verícimo, M.A. & São Clemente, S.C. (2018). Epicutaneous sensitization with nematode antigens of fish parasites results in the production of specific IgG and IgE. *J. Helminthol.*, 92(4): 403-409. <https://doi.org/10.1017/S0022149X17000633>.

Gardner, S.L. & Campbell, M.L. Parasites as probes for biodiversity. *J. Parasitol.*, 78(4): 596-600, 1992. <https://doi.org/10.2307/3283534>

Gião, T., Pelegrini, L.S., Azevedo, R.K. & Abdallah, V.D. (2020): Biodiversity of parasites found in the trahira, *Hoplias malabaricus* (Bloch, 1794), collected in the Batalha River, Tietê-Batalha drainage basin, SP, Brazil. *An. Acad. Bras. Cienc.*, 92(2): e20180610. <https://doi.org/10.1590/0001-3765202020180610>.

Gonçalves, R.A., Oliveira, M.S.B., Neves, L.R. & Tavares-Dias, M. (2016). Seasonal pattern in parasite infracommunities of *Hoplerythrinus unitaeniatus* and *Hoplias malabaricus* (Actinopterygii: Erythrinidae) from the Brazilian Amazon. *Acta Parasitol.*, 61(1): 119-129. <http://dx.doi.org/10.1515/ap-2016-0016>. PMID:26751882.

González-Amores, Y., Clavijo-Frutos, E., Salas-Casanova, C. & Alcain-Martínez, G. (2015). Direct parasitological diagnosis of infection with *Hysterothylacium aduncum* in a patient with epigastralgia. *Rev. Esp. Enferm. Dig.*, 107(11): 699-700.

Gueretz, J.S., Senger, S.B. & Claus, M.P. (2020). Ocorrência de *Ithyoclinostomum* sp. e *Eustrongylides* sp., parasitos de *Hoplias aff. malabaricus* Bloch, 1794 (Characiformes: Erythrinidae), no litoral de Santa Catarina, Brasil. *Braz. J. Dev.*, 6(4): 21565-21575. <http://dx.doi.org/10.34117/bjdv6n4-359>

Guo, Y-N., Xu, Z., Zhang, L-P., Hu, Y-H. & Li, L. (2014). Occurrence of *Hysterothylacium* and *Anisakis* nematodes (Ascaridida: Ascaridoidea) in the Tanaka's snailfish *Liparis tanakae* (Gilbert & Burke) (Scorpaeniformes: Liparidae). *Parasit. Res.*, 113(4): 1289-300. <https://doi.org/10.1007/s00436-014-3767-2>

Ignatovic, I., Stojkovic, I., Kutlesic, C. & Tasic, S. (2003) Infestation of the human kidney with *Diocotophyma renale*. *Urol. Int.*, 70(1): 70-73. <https://doi.org/10.1159/000067695>

Justino, C.H.S. & Barros, L. A. (2008). *In vitro* evaluation of the resistance of the *Contracaecum* sp. larvae (Railliet & Henry, 1912) (Nematoda: Anisakidae), to the essential oil of citronella (*Cymbopogon* sp.) (Poaceae). *R. Bras. Ci. Vet.*, 15(3): 122-125. <http://dx.doi.org/10.4322/rbcv.2014.212>

Klimpel, S. & Rückert, S. (2005). Life cycle strategy of *Hysterothylacium aduncum* to become the most abundant anisakid fish nematode in the North Sea. *Parasitol. Res.*, 97(2): 141-149. <https://doi.org/10.1007/s00436-005-1407-6>

Kohn, A., Fernandes, B.M.M., Macedo, B. & Abramson, B. (1985). Helminths parasites of freshwater fishes from Pirassununga, SP, Brazil. *Mem. Inst. Oswaldo Cruz.*, 80(3): 327-336. <https://doi.org/10.1590/S0074-02761985000300009>

Kohn, A., Fernandes, B.M.M., Pipolo, H.V. & Godoy, M.P. (1988). Helminths parasites de peixes das Usinas Hidrelétricas da Eletrosul (Brasil). II. Reservatórios de Salto Osório e de Salto Santiago, Bacia do Rio Iguçu. *Mem. Inst. Oswaldo Cruz.*, 84(3): 299-303. <http://dx.doi.org/10.1590/S0074-02761988000300006>.

Kohn, A. & Fernandes, B.M.M. (1987). Comparative study of helminths parasites of fishes from Mogi

- Guassu river, collected during expeditions between 1927 and 1985. *Mem. Inst. Oswaldo Cruz.*, 82(4): 483-500. <http://dx.doi.org/10.1590/s0074-02761987000400006>.
- Kohn, A., Moravec, F., Cohen, S.C., Canzi, C., Takemoto, R.M. & Fernandes, B.M.M. (2011). Helminths of freshwater fishes in the reservoir of the Hydroelectric Power Station of Itaipu, Paraná, Brazil. *Check List.*, 7(5): 681-690. <https://doi.org/10.15560/7.5.681>
- KØIE, M. (1993). Aspects of the life-cycle and morphology of *Hysterothylacium aduncum* (Rudolphi, 1802) (Nematoda, Ascaridoidea, Anisakidae). *Can. J. Zool.*, 71(7): 1289-1296. <https://doi.org/10.1139/z93-178>
- Kuraiem, B.P., Knoff, M., Telleria, E.L., Fonseca, M.C.G., Machado, L.S., Cunha, N.C., Nascimento, E. R., Fontenelle, G., Gomes, D.C. & São Clemente, S.C. (2020). *Eustrongylides* sp. (Nematoda, Dioctophymatoidea) parasitizing *Hoplias malabaricus* (Actinopterygii: Erythrinidae) collected from the state of Rio de Janeiro, Brazil. *Rev. Bras. Parasitol. Vet.*, 29(1): e014519. <https://doi.org/10.1590/S1984-29612019094>
- Li, L., Xu, Z. & Zhang, L-P. (2007). A new species of genus *Hysterothylacium* Ward et Magath, 1917 (Nematoda, Anisakidae) from *Liparis tanakae* (Scorpaeniformes, Liparidae) from the Yellow Sea, China. *Acta Parasitol.*, 52(4): 371-375. <https://doi.org/10.2478/s11686-007-0046-8>
- Luque, J.L., Aguiar, J.C., Vieira, F.M., Gibson, D.I. & Santos, C.P. (2011). Checklist of Nematoda associated with the fishes of Brazil. *Zootaxa.*, 3082: 1-88.
- Luque, J.L. & Poulin, R. (2007). Metazoan parasite species richness in Neotropical fishes: hotspots and the geography of biodiversity. *Parasitology.*, 134(6): 865-878, 2007. <http://dx.doi.org/10.1017/S0031182007002272>. PMID:17291392.
- Machado, M.H., Souza, G.T.R. & Ribeiro, T.S. (2013). Regulação parasitária em ecossistemas dulcícolas. In: Pavanelli, G.C.; Takemoto, R.M.; Eiras, J.C. (Eds) *Parasitologia em peixes de água doce do Brasil*. Maringá, PR, Eduem, pp. 17-35.
- Madi, R.R. & SILVA, M.S.R. (2005). *Contracaecum* Railliet & Henry, 1912 (Nematoda, Anisakidae): the parasitism related with the biology of three species of piscivorous fishes in the Jaguari reservoir, São Paulo State, Brazil. *Rev. Bras. Zool.*, 7(1): 15-24.
- Martins, M.L., Fujimoto, R.Y., Moraes, F.R., Andrade, P.M., Nascimento, A.A. & Malheiros, E.B. (2000). Description and prevalence of *Thynnascaris* sp. larvae Dollfus, 1933 (Nematoda, Anisakidae) in *Plagioscion squamosissimus* Heckel, 1840 from Volta Grande Reservoir, state of Minas Gerais, Brazil. *Rev. Bras. Biol.*, 60(3): 519-526. <https://doi.org/10.1590/S0034-71082000000300017>
- Martins, M.L., Santos, R.S., Takahashi, H.K., Marengoni, N.G. & Fujimoto, R.Y. (2003). Infection and susceptibility of three fish species from the Paraná River, Presidente Epitácio, State of São Paulo, Brazil, to *Contracaecum* sp. larvae (Nematoda: Anisakidae). *Acta Sci. Anim. Sci.*, 25(1): 73-78. <http://dx.doi.org/10.4025/actascianimsci.v25i1.2096>.
- Meneguetti, D.U.O., Laray, M.P.O. & Camargo, L.M.A. (2013). First report of *Eustrongylides* sp. larvae (Nematoda: Dioctophymatidae) in *Hoplias malabaricus* (Characiformes: Erythrinidae) in Rondônia State, Western Amazon, Brazil. *Rev. Pan-Amazônica Saúde.*, 4(3): 55-58. <http://dx.doi.org/10.5123/S2176-62232013000300008>
- Morais, A.P., Cárdenas, M.Q. & Malta, J.C.O. (2019). Nematofauna of red piranha *Pygocentrus nattereri* (Kner, 1958) (Characiformes: Serrasalminidae) from Amazonia, Brazil. *Rev. Bras. Parasitol. Vet.*, 28(3): 458-464. <https://doi.org/10.1590/S1984-29612019055>
- Moravec, F., Kohn, A. & Fernandes, B.M.M. (1993). Nematode parasites of fishes of the Paraná River, Brazil. Part 2. Seuratoidea, Ascaridoidea, Habronematoidea and Acuarioidea. *Folia Parasito. (Praha).*, 40(2): 115-134.
- Moravec, F. (1998). *Nematodes of freshwater fishes of the Neotropical Region*. Praha: Academy of Sciences of the Czech Republic.
- Oliveira, M.S.B., Corrêa, L.L., Ferreira, D.O. & Tavares-Dias, M. (2019). Larvas de nematoides de potencial zoonótico infectando peixes carnívoros do baixo Rio Jari, no Norte do Brasil. *Biota Amazôn.*, 9(4):

50-52, 2019. <http://dx.doi.org/10.18561/2179-5746/biotaamazonia.v9n4p50-52>

Oliveira, M.S.B., Corrêa, L.L., Prestes, L., Neves, L.R., Brasiense, A.R.P., Ferreira, D.O. & Tavares-Dias, M. (2018). Comparison of the endoparasite fauna of *Hoplias malabaricus* and *Hoplerythrinus unitaeniatus* (Erythrinidae), sympatric hosts in the eastern Amazon region (Brazil). *Helminthologia.*, 55(2): 157-165. <http://dx.doi.org/10.2478/helm-2018-0003>.

Overstreet, R.M. & Meyer, G. W. (1981). Hemorrhagic lesion in the stomach of rhesus monkey caused by a piscine ascaridoid nematode. *J. Parasitol.*, 67(2): 226-235.

Pantoja, C.S., Pereira, F.B., Santos, C.P. & Luque, J.L. (2016). Morphology and molecular characterization hold hands: clarifying the taxonomy of *Hysterothylacium* (Nematoda: Anisakidae) larval forms. *Parasitol. Res.*, 115(11): 4353-4364. <https://doi.org/10.1007/s00436-016-5221-0>

Paraguassu, A.R. & Luque, J.L. (2007). Metazoan parasites of six fishes species from Lajes Reservoir in the State of Rio de Janeiro, Brazil. *Rev. Bras. Parasitol. Vet.*, 16(3): 121-128, 2007. <https://doi.org/10.1590/S1984-29612007000300002>

Paraguassú, A.R. (2006). Composição e estrutura das comunidades de metazoários parasitos de sete espécies de peixes do Reservatório de Lajes, Estado do Rio de Janeiro. Tese de Doutorado, Universidade Federal Rural do Rio de Janeiro, Rio de Janeiro, Brasil.

Pavanelli, G.C., Eiras, J.C., Yamaguchi, U.M. & Takemoto, R.M. (2015). *Zoonoses humanas transmissíveis por peixes no Brasil*. UniCEsumar, Maringá, Paraná.

Pereira, E.S., Mauad, J.R.C., Takemoto, R.M. & Lima-Junior, S.E. (2018). Fish parasite diversity in the Amambai river, State Mato Grosso do Sul, Brazil. *Acta Sci. Biol. Sci.*, 40: e36330. <https://doi.org/10.4025/actascibiolsci.v40i1.36330>

Pereira, J.R.J., Almeida, F.M., Medeiros, D.E., Morais, N.C. & Vianna, R.T. (2004). *Hysterothylacium* sp. larvae (Nematoda: Anisakidae) in *Micropogonias furnieri* (Sciaenidae) from Rio Grande do Sul Coast, Brazil. *Atlântica.*, 26(1): 55-60.

Pereira, T.L. (2010). Parasitismo em *Hoplias malabaricus* (Characiformes: Erythrinidae) destinado ao consumo humano, oriundos do Lago de Furnas, Minas Gerais. Dissertação de Mestrado, Universidade Federal de Lavras, Lavras, Minas Gerais, Brasil.

Pinheiro, R.H.S., Furtado, A.P., Santos, J.N. & Giese, E.G. (2019). *Contracaecum* larvae: morphological and morphometric retrospective analysis, biogeography and zoonotic risk in the amazon. *Rev. Bras. Parasitol. Vet.*, 28(1): 12-32. <http://dx.doi.org/10.1590/s1984-29612019002>. PMID:30892463.

Pinto, R.M., De Fabio, S.P., Noronha, D. & Rolas, F.J.T. (1976). Novas considerações morfológicas e sistemáticas sobre os *Procamallanus* Brasileiros (Nematoda, Camallanoidea). *Mem. Inst. Oswaldo Cruz.*, 74(1): 77-84. <https://doi.org/10.1590/S0074-02761976000100008>

Pinto, R.M., De Fabio, S.P., Noronha, D. & Rolas, F.J.T. (1974). *Procamallanus* Brasileiros-parte 1 (Nematoda: Camallanoidea). *Mem. Inst. Oswaldo Cruz.*, 72(3-4): 205-211. <https://doi.org/10.1590/S0074-02761974000200005>

Ramos, T.P.A. (2012). Ictiofauna de água doce da Bacia do Rio Parnaíba. Tese de Doutorado, Universidade Federal da Paraíba, João Pessoa, Paraíba, Brasil.

Silva, R.T. (2014). Caracterização morfológica e molecular de endoparasitos de *Hoplias affinis malabaricus* bloch, 1794 (Characiformes: Erythrinidae) provenientes do rio Araguaia, Tocantins, Brasil. Tese de Doutorado, Universidade Federal do Tocantins, Palmas, Tocantins, Brasil.

Ribeiro, J., São Clemente, S.C., Lopes, L.M.S. & Knoff, M. (2014). Nematode larvae of hygienic importance infecting *Chaetodipterus faber* (Broussonet, 1782) and *Trachinotus carolinus* (Linnaeus, 1766) (Pisces: Teleostei) in Brazil. *Rev. Bras. Med. Vet.*, 36(2): 121-124. <https://rbmv.org/BJVM/article/view/505>

Rocha, C.A.M. (2011). Parasitic helminths of the freshwater neotropical fish *Hoplias malabaricus* (Characiformes, Erythrinidae) from South America Basins. *Rev. Fish. Sci.*, 19(2): 150-156. <http://dx.doi.org/10.1080/10641262.2011.557752>

Rodrigues, A.P. (2010). Helminthos parasitos de *Hoplias malabaricus* (Osteichthyes: Erythrinidae)

- comercializados na região sul do Rio Grande do Sul. 2010. Dissertação de Mestrado, Universidade Federal de Pelotas, Pelotas, Rio Grande do Sul, Brasil.
- Rodrigues, L.C., Santos, A.C.G., Ferreira, E.M., Teófilo, T.S., Pereira, D.M. & Costa, F.N. (2017). Parasitologic aspects of traíra (*Hoplias malabaricus*) from the São Bento city, MA. *Arq. Bras. Med. Vet. Zootec.*, 69(1): 264-268. <http://dx.doi.org/10.1590/1678-4162-8798>.
- Rodrigues, H.O., Pinto, R.M. & Noronha, D. (1991). Key to the species of Brazilian *Procamallanus* with general considerations (Nematoda, Camallanoidea). *Mem. Inst. Oswaldo Cruz.*, 86(1): 107-113, 1991.
- Rossin, M.A., Datri, L.L., Incorvaia, I.S. & Timi, J.T. (2011). A new species of *Hysterothylacium* (Ascaridoidea, Anisakidae) parasitic in *Zenopsis conchifer* (Zeiformes, Zeidae) from Argentinean waters. *Acta Parasitol.*, 56(3): 310-314. <https://doi.org/10.2478/s11686-011-0062-6>
- Santos, G.M., Ferreira, E.J.G. & Zuanon, J.A.S. (2006). *Peixes comerciais de Manaus*. Manaus: Ibama/AM; ProVárzea.
- Shamsi, S. & Butcher, A.R. (2011). First report of human anisakidosis in Australia. *Med. J. Aust.*, 194(4): 199-200. <https://doi.org/10.5694/j.1326-5377.2011.tb03772.x>
- Takemoto, R.M., Pavanelli, G.C., Lizama, M.A.P., Lacerda, A.C.F., Yamada, F.H., Moreira, L.H.A., Ceschini, T.L. & Bellay, S. (2009). Diversity of parasites of fish from the Upper Paraná River floodplain, Brazil. *Braz. J. Biol.*, 69(2): 691-705. <https://doi.org/10.1590/s1519-69842009000300023>. PMID:19738975.
- Thatcher, V.E. (2006). *Amazon fish parasites*. Sofia-Moscow: Pensoft.
- Thobois, S., Broussolle, E., Aimard, G. & Chazot, G. (1996). Ingestion of raw fish: a cause of eosinophilic meningitis caused by *Angiostrongylus cantonensis* after a trip to Tahiti. *Presse. Med.*, 25(10): 508.
- Vicente, J.J. & Pinto, R.M. (1999). Nematóides do Brasil. Nematóides de peixes. Atualização: 1985-1998. *Rev. Bras. Zool.*, 16(3): 561-610. <http://dx.doi.org/10.1590/S0101-81751999000300001>
- Vicente, J.J., Rodrigues, H.O. & Gomes, D.C. (1985). Nematóides do Brasil. 1ª parte: nematóides de peixes. *Atas Soc. Biol. Rio de Janeiro.*, 25(1): 1-79.
- Vieira, K.R.I., Vincentin, W., Paiva, F., Pozo, C.F., Borges, F.A., Adriano, E.A., Costa, F.E.S. & Tavares, L.E.R. (2010). *Brevimulticaecum* sp. (Nematoda: Heterocheilidae) larvae parasitic in freshwater fish in the Pantanal wetland, Brazil. *Vet. Parasitol.*, 172(3-4): 350-354. <http://dx.doi.org/10.1016/j.vetpar.2010.05.003>
- Vieira-Menezes, F.G., Costa, D.P.C. & Brasil-Sato, M.C. (2017). Nematodes of *Astyanax fasciatus* (Actinopterygii: Characidae) and their parasitic indices in the São Francisco River, Brazil. *Rev. Bras. Parasitol. Vet.*, 26(1): 10-16. <http://dx.doi.org/10.1590/s1984-29612016074>.
- Weiblen, A.M. & Brandão, D.A. (1992). Levantamento parasitológico em *Hoplias malabaricus*, Bloch, (1749) (traíra) de águas da região de Santa Maria – RS. *Ciênc. Rural.*, 22(2): 203-208. <http://dx.doi.org/10.1590/S0103-84781992000200014>.
- Yagi, K., Nagasawa, K., Ishikura, H., Nakagawa, A., Sato, N., Kikuchi, K. & Ishikura, H. (1996). Female worm *Hysterothylacium aduncum* excreted from human. A case report. *JPN J. Parasitol.*, 45(1): 12-13.